

Paratuberculosis in a mandrill (*Papio sphinx*)

Laura S. Zwick, Timothy F. Walsh, Robyn Barbers, Michael T. Collins, Michael J. Kinsel, Robert D. Murnane

Abstract. A 2.5-year-old captive female mandrill (*Papio sphinx*) died following a protracted course of intermittent abdominal bloat, diarrhea, and severe weight loss. Necropsy revealed emaciation and marked gastrointestinal distention with gas and ingesta. Histologic evaluation revealed severe diffuse granulomatous enterocolitis and mesenteric lymphadenitis with massive numbers of 1–2- μ m acid-fast bacilli within macrophages. Additionally, there was moderate to severe multifocal myocardial and vascular amyloidosis, moderate multifocal pyogranulomatous interstitial pneumonia with no acid-fast bacteria, and moderate multifocal glossal candidiasis. Samples of feces, ileum, and colon were positive for *Mycobacterium avium* subsp. *paratuberculosis* by radio-metric culture and a polymerase chain reaction-amplified DNA probe specific for the insertion sequence IS900 of this organism.

Paratuberculosis (Johne's disease) is a chronic progressive granulomatous intestinal disease of wild and domestic ruminants with a worldwide distribution.^{1–3} The disease is caused by infection with *Mycobacterium avium* subsp. *paratuberculosis*, an acid-fast, weakly gram-positive bacillus.^{2,3} Experimental infections with this organism have been produced in pigs, horses, pigeons, chickens, and laboratory animals including mice, hamsters, guinea pigs, and rabbits.^{1,3,5,6–9,11,12,14}

One report of naturally occurring confirmed paratuberculosis in nonhuman primates has been described in the literature.¹⁰ The outbreak affected 29 of 38 individuals in a colony of stump-tail macaques (*Macaca arctoides*). The clinical and pathologic features of paratuberculosis in this species were comparable with those reported for paratuberculosis in ruminants and *M. a.* subsp. *avium* infections in primates. In recent years, *M. a. paratuberculosis* has also been implicated as a possible cause of Crohn's disease in humans, although a causal relationship has not been definitively established.^{11,13} This report documents a case of paratuberculosis in a mandrill (*Papio sphinx*).

A 21-month-old intact female mandrill arrived at Lincoln Park Zoo, Chicago, Illinois, and was placed in 30-day quarantine. Routine physical examination, thoracic and abdominal radiographs, a serum chemistry profile, and a complete blood count were within normal limits. An intradermal tuberculin test and fecal cultures for enteric pathogens including *Campylobacter* sp. and *Salmonella* spp. were negative. Serology was reported as negative for herpesvirus SA8, *Herpes simiae* (Herpes B), measles, simian immunodeficiency virus, simian retroviruses (1, 2, and 5), simian T-cell leu-

kemia virus-1, and encephalomyocarditis virus, while positive for cytomegalovirus.

Approximately 2 months after arrival, this individual developed intermittent watery diarrhea, abdominal bloat, and progressive weight loss. The animal's condition continued to decline in spite of enhanced caloric supplementation via nasogastric tube in advanced stages of disease. Death occurred shortly after exploratory surgery was performed 7 months following the advent of clinical signs.

At necropsy, the animal was in fair postmortem condition and emaciated with a severely distended abdomen. The stomach was markedly distended with ingesta, and the intestines were severely distended, with large amounts of ingesta and gas. Lymph nodes throughout the body were prominent. Representative samples of all organs were fixed in 10% neutral buffered formalin, routinely processed for histopathology, sectioned at 3–6 μ m, and stained with hematoxylin and eosin. Selected sections were also stained with Ziehl–Neelsen and Congo red stains.

Histologic evaluation revealed variable degrees of granulomatous inflammation throughout the intestinal mucosa extending from the duodenum through the colon, with the ileocecal junction being the most severely affected region. The intestinal lamina propria was diffusely expanded by moderate to severe accumulations of large, occasionally binucleated, epithelioid macrophages admixed with scant to moderate numbers of lymphocytes and plasma cells. The small intestine had severe, multifocal villus atrophy with extensive crypt loss and rare crypt abscesses (Fig. 1). Inflammatory cell infiltrates frequently extended into the submucosa (Fig. 2). Ziehl–Nielsen stains revealed massive numbers of 1–2- μ m-long acid-fast bacilli within macrophages in affected areas (Fig. 3). Mesenteric and ileal lymph nodes had mild to moderate diffuse lymphocyte depletion and edema and contained variably small to moderate numbers of acid-fast bacteria-laden macrophages within subcapsular and medullary sinuses and rarely within lymphoid follicles. Blood vessels throughout the gastrointestinal tract and mesentery often had moderate to severe segmental to diffuse mural and perivascular accumulations of amyloid, and there was also moderate to severe multifocal myocardial amyloid-

From the Zoological Pathology Program, University of Illinois College of Veterinary Medicine, Loyola University Medical Center, Room 0745, Building 101, 2160 South First Avenue, Maywood, IL 60153 (Zwick, Kinsel, Murnane), Washington State University, College of Veterinary Medicine, Pullman, WA 99164-7012 (Walsh), Lincoln Park Zoological Gardens, 2001 North Clark Street, Chicago, IL 60614 (Barbers), and the Department of Pathobiological Sciences, School of Veterinary Medicine, University of Wisconsin, Madison, WI 53706-1102 (Collins).

Received for publication September 5, 2001.

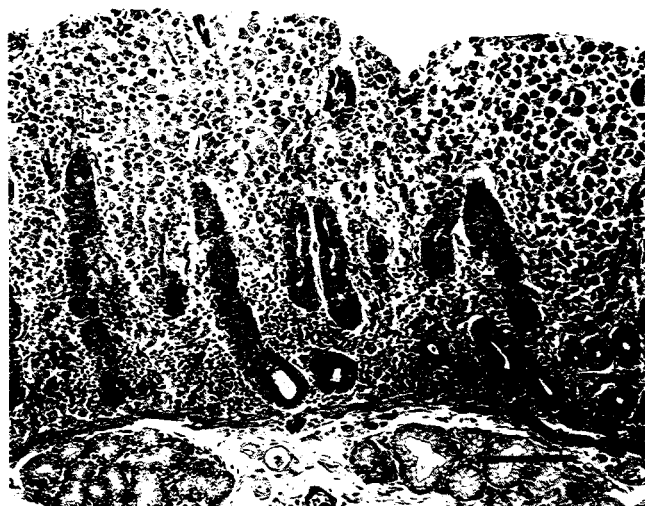


Figure 1. Section of duodenum from a mandrill with paratuberculosis. Note extensive histiocytic infiltrate in the lamina propria with severe villus atrophy and crypt loss. Hematoxylin and eosin stain. Bar = 100 μ m.

osis. The Congo red-staining affinity of amyloid deposits was sensitive to potassium permanganate oxidation, consistent with amyloid of the AA type. Additionally, this individual had moderate multifocal pyogranulomatous interstitial pneumonia with no acid-fast bacteria and moderate multifocal lingual candidiasis.

Cultures of feces, ileum, and colon were processed for isolation of *M. a. paratuberculosis* using a radiometric culture medium, as previously described.⁴ Tissues were homogenized with an equal volume of sterile saline in a Stomacher. Three grams of homogenized tissue suspension or feces was mixed with 30 ml of 1.0% hexadecylcetylpyridinium chloride (HPC). After overnight decontamination settling, the uppermost 10 ml of the suspension was aspirated into a syringe and filter concentrated using a 13-mm-diameter 3- μ m-pore-diameter polycarbonate filter^a in a Swinex filter holder.^b The filter was placed into a commercial 12B bottle^c supplemented with 1.0 ml egg yolk suspension,^d mycobactin J^e (1 μ m/ml), vancomycin (10 μ m/ml), amphotericin B (20 μ m/ml), and nalidixic acid (30 μ m/ml). Growth was monitored weekly on a commercial mycobacterial detection and susceptibility testing system.^f Growth of acid-fast bacteria was detected after 4–6 weeks. The *Mycobacterium* species isolated in each vial was confirmed to be *M. a. paratuberculosis* using a commercial polymerase chain reaction (PCR)-amplified DNA probe for IS900^g proven to be specific for the organism.¹⁵ Mycobacterial cultures of feces performed at the National Veterinary Services Laboratory in Ames, Iowa, yielded no growth.

In summary, the prolonged disease course was attributed to infection with *M. a. paratuberculosis*, and death was due to the combined effects of this infection and myocardial amyloidosis, exacerbated by the stress of surgery and anesthesia. Infection with *M. a. paratuberculosis* likely occurred at a young age in this individual, similar to the development of Johne's disease in ruminants,^{1–3} although the source of



Figure 2. Section of cecum from a mandrill. Note histiocytic infiltrate within the lamina propria and submucosa, with associated crypt loss. Hematoxylin and eosin stain. Bar = 100 μ m.

infection in this animal is unknown. To date, there have been no additional cases of clinical paratuberculosis in exposed mandrills at this institution or the institution of origin.

To the author's knowledge, the only previously reported naturally occurring cases of paratuberculosis in nonhuman primates occurred in stump-tail macaques.¹⁰ Histologic lesions noted in the intestines and mesenteric lymph nodes in the case reported here were similar to the spectrum of lesions reported in the colony of stump-tail macaques, with the exception of vascular and myocardial amyloidosis, which probably developed secondary to chronic inflammatory processes. Mandrills and stump-tail macaques are both cercopithecines, and this may indicate familial susceptibility to *M. a. paratuberculosis* infection.

This case emphasizes the importance of fecal and tissue cultures for specific identification of mycobacteria, particularly considering the potential risk for zoonotic infections

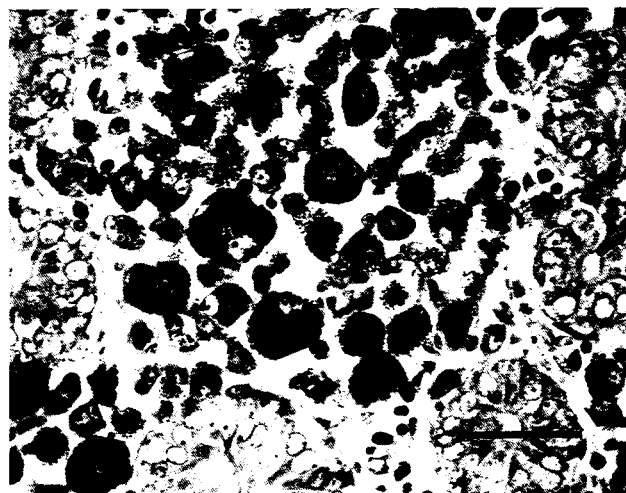


Figure 3. Section of duodenum from a mandrill. Macrophages within the lamina propria contain large numbers of acid-fast bacilli. Ziehl-Neelsen stain. Bar = 40 μ m.

associated with these organisms. Possibly, past cases of paratuberculosis in nonhuman primates were misdiagnosed as *Mycobacterium avium* subsp. *avium* infection prior to the advent of DNA probe technology.

Acknowledgements. The authors would like to acknowledge the excellent technical assistance of Ms. Debra Teubert, Department of Pathobiological Sciences, School of Veterinary Medicine, University of Wisconsin, the Hines Veterans Administration Hospital Histology Laboratory, Jane Chladny and the Histopathology Laboratory of the University of Illinois Veterinary Diagnostic Laboratory, and the hospital staff and primate keepers at the Lincoln Park Zoo.

Sources and manufacturers

- a. BACTEC, Becton Dickinson Microbiologic Systems, Sparks, MD.
- b. Millipore Corp., Bedford, MA.
- c. Nuclepore Corp., Pleasanton, CA.
- d. Difco, Detroit, MI.
- e. Allied Monitor, Fayette, MO.
- f. BACTEC 460TB, Becton Dickinson Microbiologic Systems, Sparks, MD.
- g. IDEXX Laboratories, Inc., Westbrook, ME.

References

1. Barker IK, Van Dreumel AA, Palmer N: 1993. The alimentary system. In: Pathology of domestic animals, eds. Jubb KVF, Kennedy PC, Palmer N, 4th ed., pp. 247–252. Academic Press, San Diego, CA.
2. Clarke CJ: 1997. The pathology and pathogenesis of paratuberculosis in ruminants and other species. *J Comp Pathol* 116:217–261.
3. Cocito C, Gilot P, Coene M, et al.: 1994. Paratuberculosis. *Clin Microbiol Rev* 7:328–345.
4. Collins MT, Kenefick KB, Sockett DC, et al.: 1990. Enhanced

- radiometric detection of *Mycobacterium paratuberculosis* by using filter-concentrated bovine fecal specimens. *J Clin Microbiol* 28:2514–2519.
5. Collins P, Matthews PRJ, McDiarmid A, Brown A: 1983. The pathogenicity of *Mycobacterium avium* and related mycobacteria for experimental animals. *J Med Microbiol* 16:27–35.
6. Hamilton HL, Cooley AJ, Adams JL, Czuprynski CJ: 1991. *Mycobacterium paratuberculosis* monoassociated nude mice as a paratuberculosis model. *Vet Pathol* 28:146–155.
7. Hamilton HL, Follett DM, Siegfried LM, Czuprynski CJ: 1989. Intestinal multiplication of *Mycobacterium paratuberculosis* in athymic nude gnotobiotic mice. *Infect Immun* 57:225–230.
8. Larsen AB, Moon HW, Merkal RS: 1971. Susceptibility of swine to *Mycobacterium paratuberculosis*. *Am J Vet Res* 32:589–595.
9. Larsen AB, Moon HW, Merkal RS: 1972. Susceptibility of horses to *Mycobacterium paratuberculosis*. *Am J Vet Res* 33:2185–2189.
10. McClure HM, Chiodini RJ, Anderson DC, et al.: 1987. *Mycobacterium paratuberculosis* infection in a colony of stump-tail macaques (*Macaca arctoides*). *J Infect Dis* 155:1011–1019.
11. Mokresh AH, Butler DG: 1990. Granulomatous enteritis following oral inoculation of newborn rabbits with *Mycobacterium paratuberculosis* of bovine origin. *Can J Vet Res* 54:313–319.
12. Mokresh AH, Czuprynski CJ, Butler DG: 1989. A rabbit model for the study of *Mycobacterium paratuberculosis* infection. *Infect Immun* 57:3798–3807.
13. Thomson DE: 1994. The role of mycobacteriosis in Crohn's disease. *J Med Microbiol* 41:74–94.
14. VanKruiningen HJ, Ruiz B, Gumprecht L: 1991. Experimental disease in young chickens induced by a *Mycobacterium paratuberculosis* isolate from a patient with Crohn's disease. *Can J Vet Res* 55:199–202.
15. Vary PH, Andersen PR, Green E, et al.: 1990. Use of highly specific DNA probes and the polymerase chain reaction to detect *Mycobacterium paratuberculosis* in Johne's disease. *J Clin Microbiol* 28:933–937.

J Vet Diagn Invest 14:328–331 (2002)

Metastatic pulmonary adenocarcinoma in a llama (*Lama glama*)

José A. Ramos-Vara, Margaret A. Miller

Abstract. An adult female llama with a comminuted fracture of the left femoral head was necropsied. A firm multinodular mass infiltrated skeletal muscle adjacent to the fracture. Multiple, firm, white nodules were in the pulmonary parenchyma and pleura. A single nodule was in the liver. Microscopically, transition from nonneoplastic bronchiolar epithelium to neoplastic epithelium that formed acinar structures was evident at bronchioloalveolar junctions. A diagnosis of pulmonary adenocarcinoma was made. Similar neoplastic tissue was in the liver and in the perifemoral mass. Immunohistochemically, neoplastic cells were positive for pan-cytokeratin, cytokeratin 7, and cytokeratin 5/6 antibodies and negative for vimentin and cytokeratins 8/18 and 20.

A 160 kg adult female llama was submitted to the Veterinary Medical Diagnostic Laboratory of the University of

Missouri for necropsy. This llama developed sudden lameness of the right rear limb. The attending veterinarian noticed crepitus at the right coxofemoral joint and suspected fracture of the proximal femur. Euthanasia was elected. On gross examination, this llama was in good nutritional condition and had abundant edema in the proximal subcutaneous

From the Veterinary Medical Diagnostic Laboratory, University of Missouri, PO Box 6023, Columbia, MO 65205.

Received for publication July 10, 2001.