

December 17, 2018

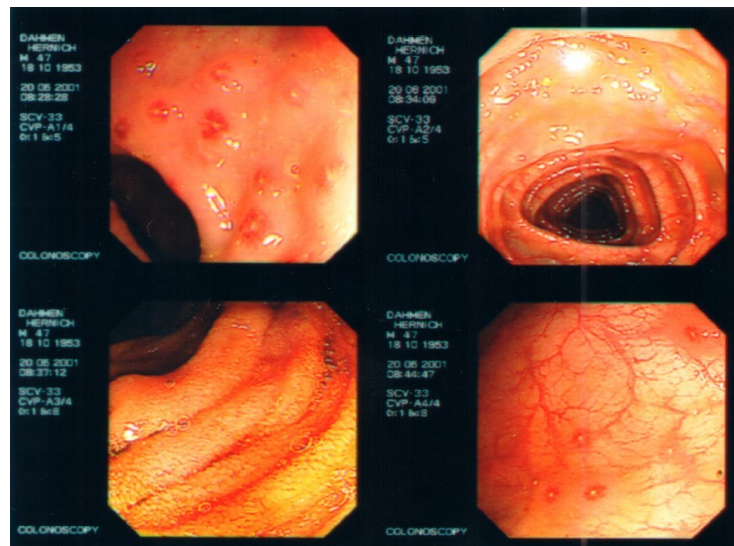
Dear Mike,  
This is my story:

Until November 2000 I was perfectly well. Then, I began to notice an increasing stool frequency. Early in 2001 I developed abdominal pain and mouth ulcers and noticed that I was suffering from lack of energy. In April 2001 I also noticed bloody stools. A colonoscopy showed an inflammation of the left colon consistent with Crohn's disease.

My doctor wanted to put me on mesalazine, a common anti-inflammatory drug at that time, but I refused. I had a vague memory of a possible link between Crohn's disease and Johne's disease.

A friend of mine, Prof. Wolfgang Klee from the veterinary school at the University of Munich gave me Prof. M. Collins phone number and in May 2001 I called him. Dr. Collins referred me to Prof. John Hermon-Taylor in London.

In London, I had a second ileocolonoscopy at London Bridge Hospital on June 20, 2001, performed by Dr. Jeremy Sanderson. This exam found aphthous ulcers and colitis in the recto-sigmoid region. Mucosal biopsies were obtained for PCR and culture testing for MAP. Serum was obtained to examine for antibodies against selected MAP proteins. All three biopsies from the inflamed sigmoid colon and rectum were PCR-positive for MAP. This was supported by the additional finding that I had elevated IgG antibodies against recombinant AhpC antigen of MAP.



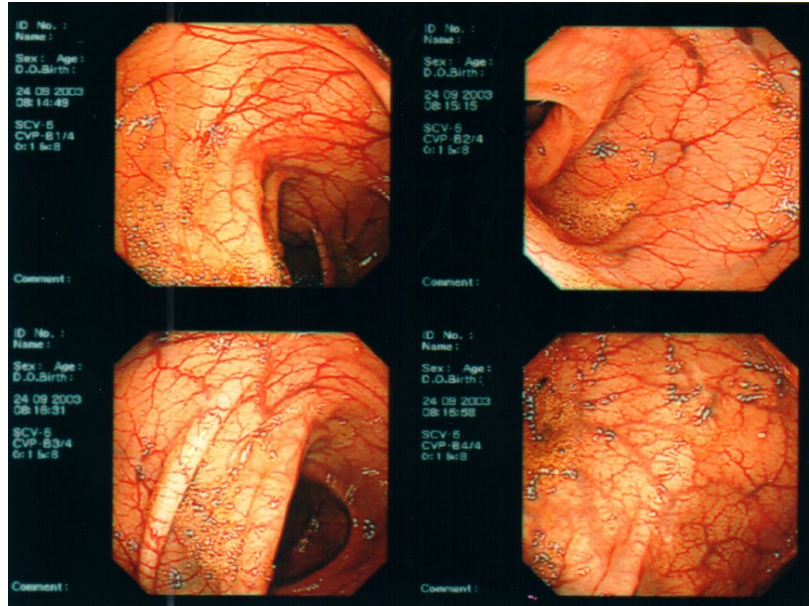
I was treated for two years with 150 mg rifabutin and 250 mg clarithromycin in the morning and 150 mg rifabutin and 500 mg clarithromycin in the evening. Beginning in November 2001, I also took 50 mg clofazimine once a day.

After two or three weeks I had a mild Jarisch-Herxheimer reaction due to the destruction of MAP and release of its antigens. Thus, all medications were stopped. After a week, I started the initial therapy again starting with low antibiotic doses which gradually increased to the full dosages.

By late fall 2001 I felt perfectly well again, and all the symptoms of Crohn's disease had gone. However, on Dr. Hermon-Taylor's advice I continued the medication until August 2003.

A follow-up colonoscopy was carried out on September 24, 2003 at London Bridge Hospital, again by Dr. J. Sanderson. Again, tissue samples were collected. The results of the colonoscopy and histology were "normal gut". The IS900 Nested PCRs on all biopsies were negative too. I was healed!!

It's now 15 years later (fall 2018) and I'm still in good shape and continuing to practice veterinary medicine in Germany, thanks to the great work of Prof. John Hermon-Taylor.



How did I acquire a MAP infection? There are two possibilities: 1) I consumed raw milk over long periods during my childhood, and/or 2) I am regularly exposed cattle with Johne's disease in my large animal practice.

All the best,  
Heinrich  
Dr.med. vet. Heinrich Dahmen



*Photo of Heinrich taken at the 7-ICP in Mexico, June 2018.*